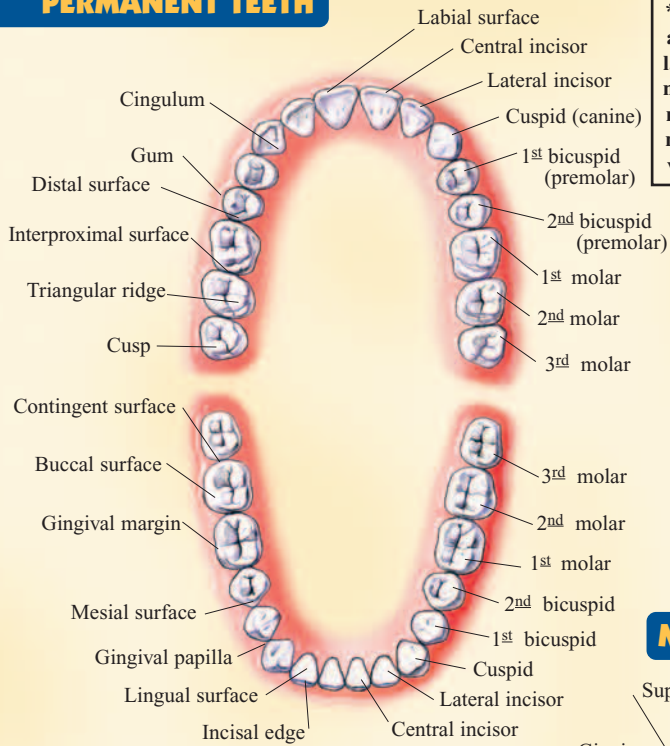


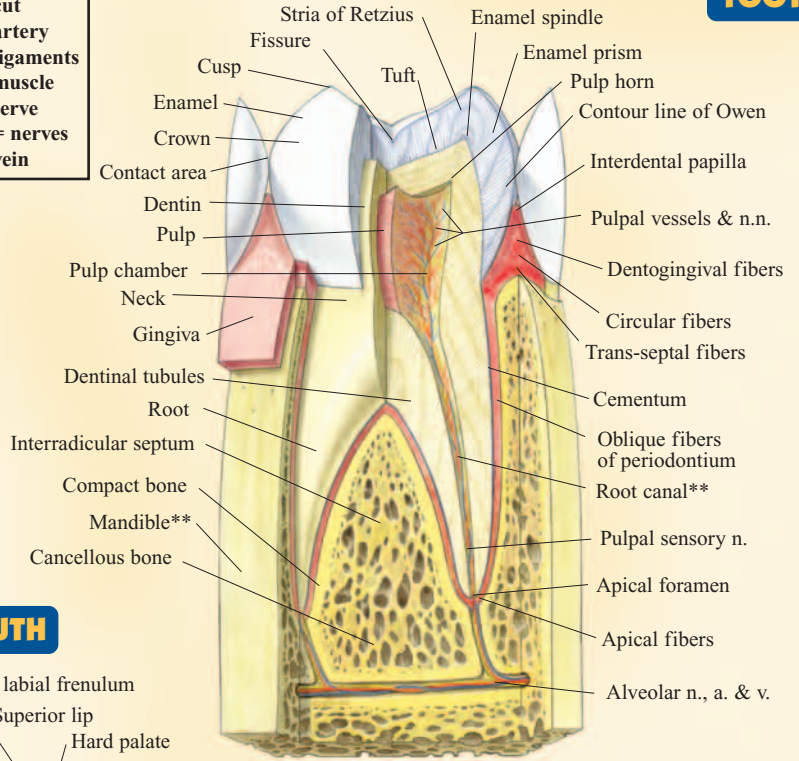
DENTAL ANATOMY

PERMANENT TEETH



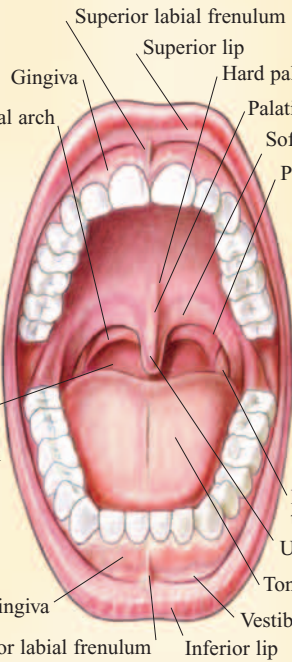
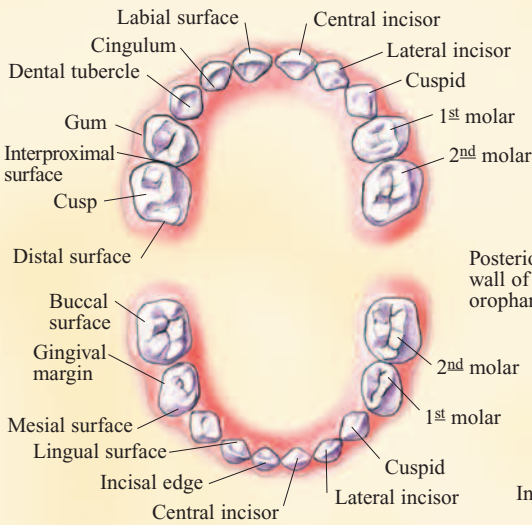
**** = cut**
a. = artery
l.l. = ligaments
m. = muscle
n. = nerve
n.n. = nerves
v. = vein

TOOTH

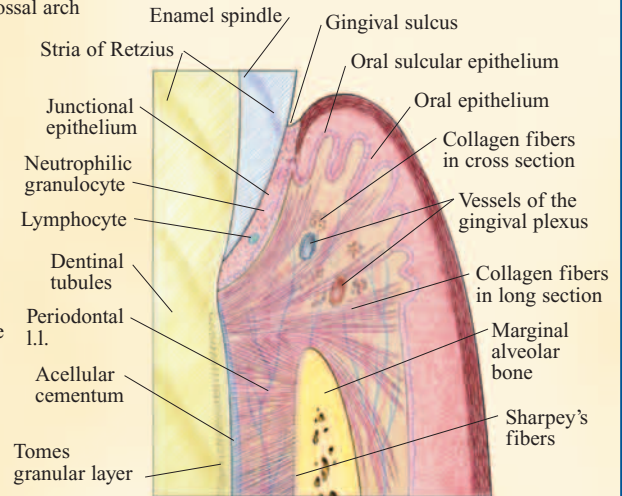


MOUTH

DECIDUOUS ARCH

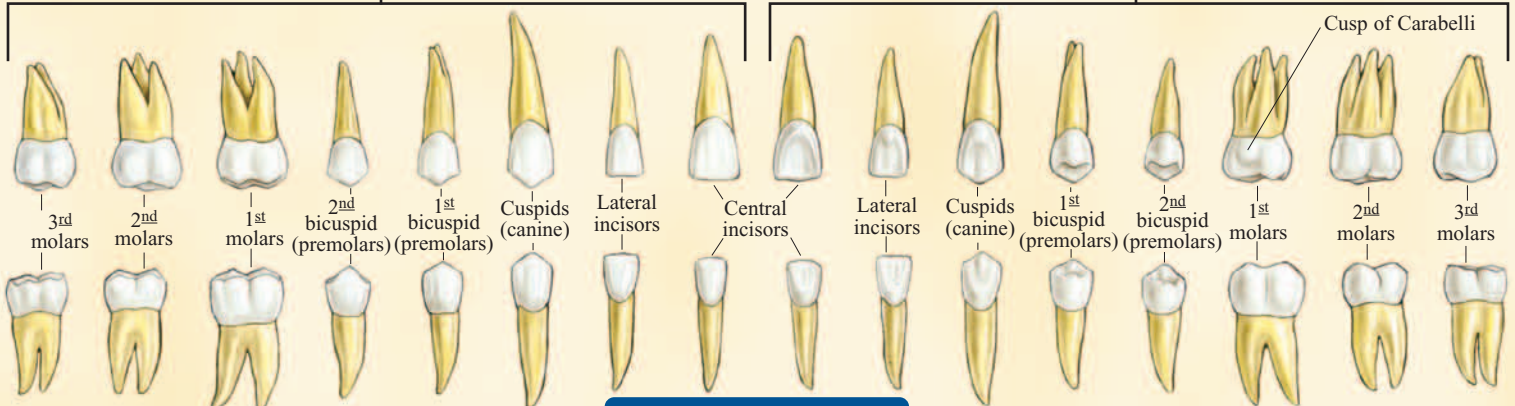


MARGINAL GINGIVA

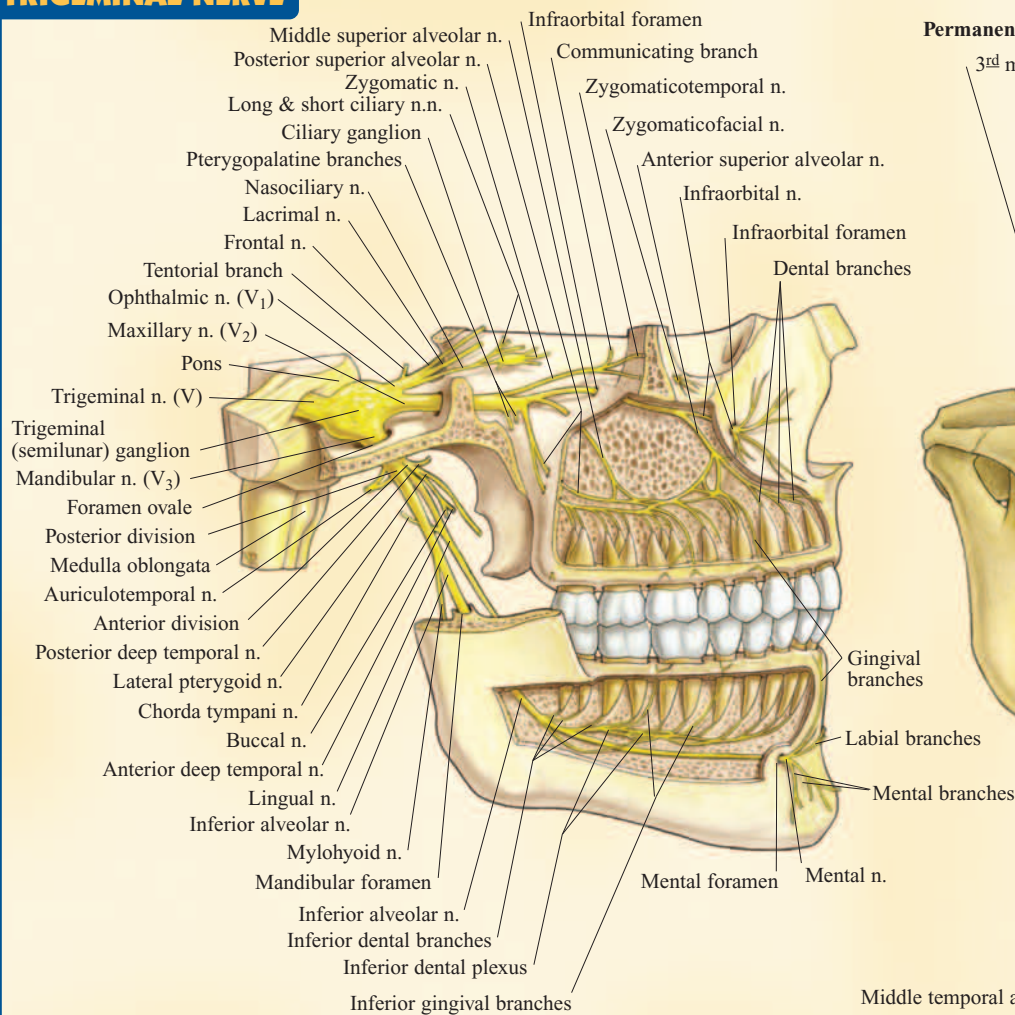


Facial View

Lingual View

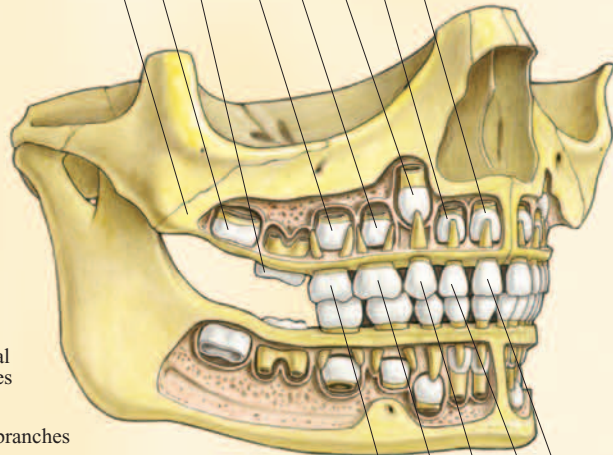


PERMANENT TEETH



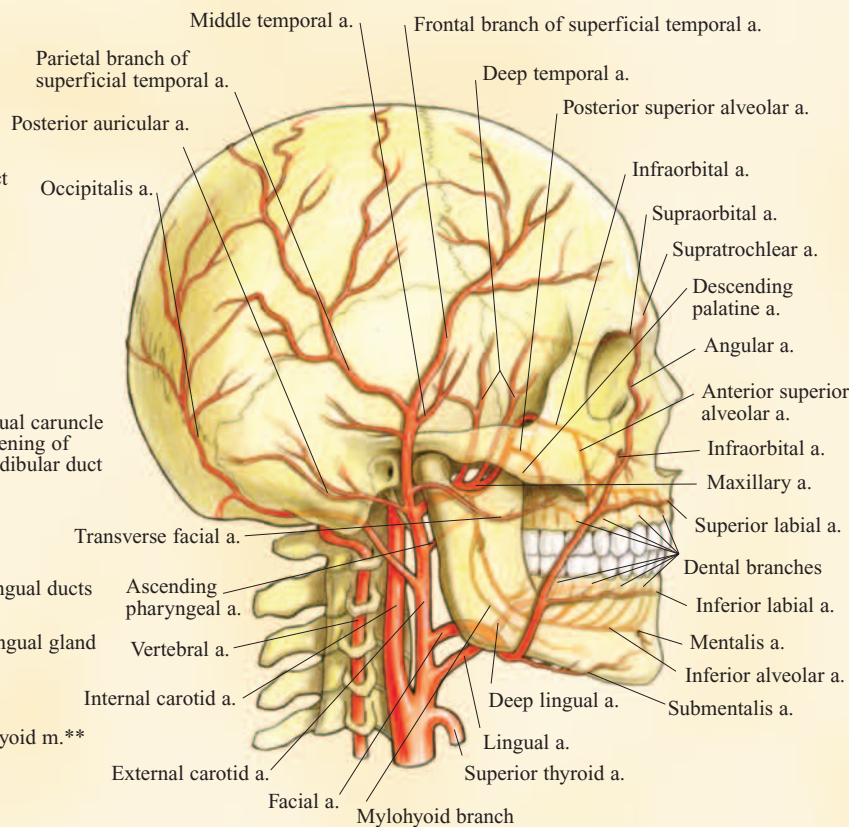
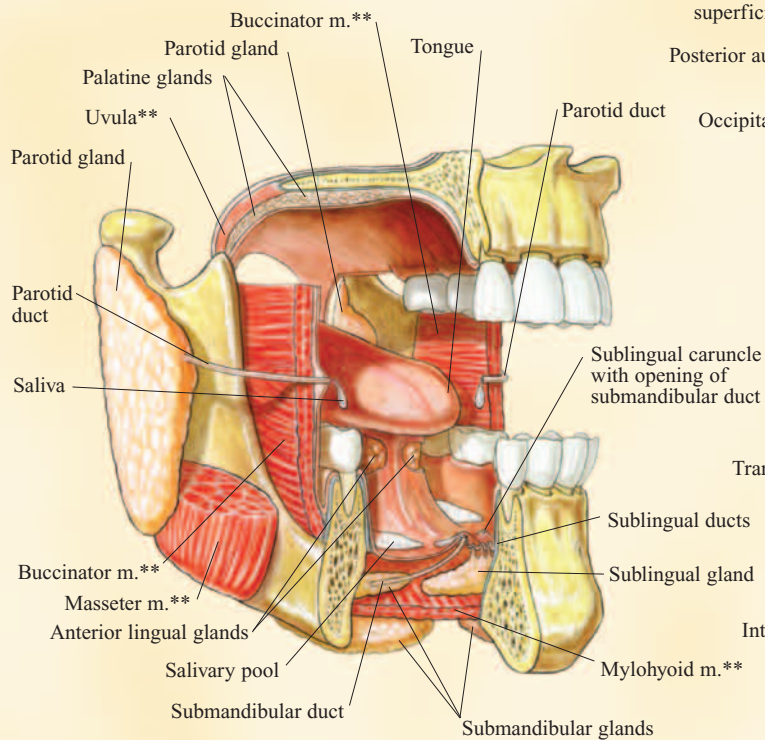
Permanent teeth:

- 3rd molar (wisdom tooth) (not illustrated) 17-25 yr.
- 2nd molar 12-13 yr.
- 1st molar 6-7 yr.
- 2nd bicuspid (premolar) 12-13 yr.
- 1st bicuspid (premolar) 11 yr.
- Cuspid (canine) 11 yr.
- Lateral incisor 8 yr.
- Central incisor 7 yr.



Deciduous teeth:

- 2nd molar 2 yr.
- 1st molar 10-15 mo.
- Canine (eyetooth) 16-20 mo.
- Lateral incisor 8-10 mo.
- Central incisor 6-8 mo.



MOUTH & SALIVARY GLANDS

SKULL & ARTERIES

U.S.\$3.95 / CAN.\$5.95 Images © Vincent Perez/perezstudio.com
Layout: Rich Marino

NOTE TO STUDENT: Use this comprehensive QuickStudy® study guide in the classroom, at home or anywhere you need complete information about the digestive system. This guide is not designed to take the place of classroom attendance.

All rights reserved. No part of this publication may be reproduced or transmitted in any form, or by any means, electronic or mechanical, including photocopy, recording, or any information storage and retrieval system, without written permission from the publisher. ©2004 BarCharts Inc. 0308

ISBN-13: 978-142320721-4
ISBN-10: 142320721-1



Customer Hotline # 1.800.230.9522

free downloads & hundreds of titles at
quickstudy.com



6 54614 00721 6